



PATIENT

Matilda Hector

PRESENTING CLINICAL SIGNS

Potential seizures vs syncope elevated LE's

Abnormal PE/Chem/CBC/UA Results: ALP 1749 Glob 4.6

SPECIES

Canine

ULTRASONOGRAPHIC EXAMINATION OF THE ABDOMEN AND HEART

BREED

Mixed

SEX

FS

AGE

11

WEIGHT

42.6

CANINE CARDIAC PARAMETERS	MR VMAX (m/s)	TR VMAX (m/s)	LA/AO M-mode	LA/AO (Heart Base; Swe)	FS (%)	EF (%)	EPSS (cm)
NORMAL PARAMETER	4.5-5.5	<2.7	1.3	Up to 1.6	28-40	40-100	<0.6
PATIENT	--	--	--	1.0	38	69	0.2
CANINE CARDIAC PARAMETERS	HR (BPM)	AV VMAX (m/s)	PV MAX (m/s)	BODY WEIGHT	LAD LA MAX 4 Chamber	LVIDd Avg; 2D and m-mode short axis (cm)	LVIDs Avg; 2D and m-mode short axis (cm)
NORMAL PARAMETER	50-100	0.7-1.7	0.7-1.6				
PATIENT	NM	1.5	1.0	42.6	3.6	3.5	--

Cardiac Presentation

INTERPRETED BY

R. McKenzie Daniel, DVM, DABVP (Canine and Feline)

The echocardiogram in this patient demonstrated normal left atrial size based on 2 separate methods of LA evaluation. The cranial and caudal mitral valve leaflets presented normal linear structure, extension in systole, and union in diastole with normal kinesis. No overt MR on Doppler. The left ventricle presented thicknesses with linear contour and was not dilated nor restricted. The myocardium presented normal echogenicity without subjective evidence of significant fibrotic or ischemic disease. Contractility of the ventricular walls was adequate and in normal range for this patient evidenced by the fractional shortening measurement and subjective evaluation of the different regions of the myocardium. The left ventricular outflow tract demonstrated normal laminar flow and subjective structural integrity. Normal measured LVOT velocity. The right atrium and auricle revealed normal size, structure and content. No evidence of masses was noted. Tricuspid valvular assessment demonstrated adequate linear morphology and kinesis. No overt TR on Doppler. The right ventricle was of normal size (1/3 diameter of LV), chordae structure, myocardial echogenicity and thickness. Pulmonary outflow tract assessment revealed normal valve structure, laminar flow, and diameter (approx.1:1 pa/ao ratio). Normal measured RVOT velocity. No visible pericardial or free pleural fluid was noted. The cranial mediastinum and pericardial and extra-cardiac regions were free of masses in the visible window. No evidence of arrhythmia.

IMAGING PERFORMED BY

Jenn

HOSPITAL NAME

Rockaway Animal Hospital

REFERRING VET

Dr Dubos

Urinary System

The urinary bladder, trigone, cystourethral junction, and visible pelvic urethra to a depth of 3 cm exhibited normal thickness and tone. Anechoic urine was present in the lumen with no evidence of urine/lumen sediment, mineral, or calculi. The ureteral papillae were normal. The ureters were not visible which is normal. No evidence of inflammatory or neoplastic changes was noted.

INVOICE 24939

DATE
05/26/2026



PATIENT

Matilda Hector

SPECIES

Canine

BREED

Mixed

SEX

FS

AGE

11

WEIGHT

42.6

INTERPRETED BY

R. McKenzie Daniel,
DVM, DABVP
(Canine and Feline)

IMAGING PERFORMED BY

Jenn

HOSPITAL NAME

Rockaway Animal
Hospital

REFERRING VET

Dr Dubos

INVOICE
24939

DATE
05/26/2026

Normal size and margination were present in the kidneys. A normal 1:3 cortex / medulla ratio was maintained. The medulla and cortices were uniform in texture with some increased echogenicity and mild loss of corticomedullary symmetry and definition expected for the age of the patient. No evidence of pelvic dilation was present. The left kidney measured 6.7 cm in length. The right kidney measured 6.7 cm in length.

The area of the aortic trifurcation was free of pathology.

Adrenal Glands

The left adrenal gland was borderline enlarged in size with a uniformly hypoechoic parenchyma. The left adrenal gland measured 0.78 cm width at the caudal pole. The right adrenal gland was not definitively visualized, no overt pathology in the area of the right adrenal gland.

Spleen

The spleen exhibited a finely textured and homogenous parenchyma which was hyperechoic to the liver and renal cortical parenchyma. The capsule was smooth and regular without apparent expansion. The splenic vasculature at the hilus was normal in volume with no evidence of congestion or thrombosis. Acute to chronic inflammatory, neoplastic, or benign parenchyma changes were not noted.

Liver/Gallbladder

The liver presented mildly enlarged in size. The parenchyma of the liver was subjectively normal in echogenicity compared to the spleen and renal cortices. The liver parenchyma was uniform with a mildly coarse echotexture. The capsule of the liver was symmetrically rounded to mildly swollen in margination. Normal vascular volume. The hepatic and portal vasculature were normal in appearance without signs of congestion. The gallbladder was non-distended in size with primarily anechoic luminal content. The cystic and common bile ducts were normal.

Gastrointestinal

The stomach presented intact wall layering with a normal wall layer ratio. The lumen of the stomach contained mild non-shadowing chyme with a small linear like hyperechoic shadowing lumen echo. No evidence of obstruction to pyloric outflow. The echo measured ~ 1.5 cm in length.

The small intestine presented intact wall layering with 1:3 muscularis/mucosa ratio. The lumen of the small intestine was empty with no signs of mechanical/metabolic ileus, obstruction or foreign material.

Normal visible colon wall layers were present with apparent formed feces in lumen.

Pancreas

The parenchyma of the left limb, body and right limb of the pancreas presented isoechoic to the adjacent omental fat. A normal curvilinear capsule contour of the pancreas was present. The visible pancreatic duct was normal. No signs of active inflammation or neoplastic disease was evident.

Free Abdomen

No omental masses, overt lymphadenopathy or peritoneal effusion was present.

ULTRASONOGRAPHIC FINDINGS

Primary



PATIENT

Matilda Hector

- Normal cardiac structure / function
- Hepatopathy exhibiting adequate hepatic vascular volume
- Normal gallbladder
- Age-related renal changes
- Borderline left adrenomegaly
- Small non-obstructive non-specific shadowing gastric lumen echo

SPECIES

Canine

INTERPRETATION OF THE FINDINGS & FURTHER RECOMMENDATIONS

BREED

Mixed

No evidence of cardiomyopathy, arrhythmia or abdominal visceral pathology as a definitive cause of potential seizure activity. The liver suggests benign criteria such as vacuolar/ cholestatic hepatopathy given ALP elevation, non-obvious inflammation considered less likely with no evidence of hepatic intra-abdominal neoplastic criteria or hepatic vascular anomaly.

SEX

FS

Bile acid profile could be considered if concern for hepatic dysfunction i.e. abnormal BUN, GLU, CHOL or GLU levels. Correlation with ECG and neurological exam is recommended. Hepatosupportive medications may prove beneficial. Adrenal screening could be considered if clinical suspicion of adrenal disease.

AGE

11

WEIGHT

42.6

INTERPRETED BY

R. McKenzie Daniel,
DVM, DABVP
(Canine and Feline)

IMAGING PERFORMED BY

Jenn

HOSPITAL NAME

Rockaway Animal
Hospital

REFERRING VET

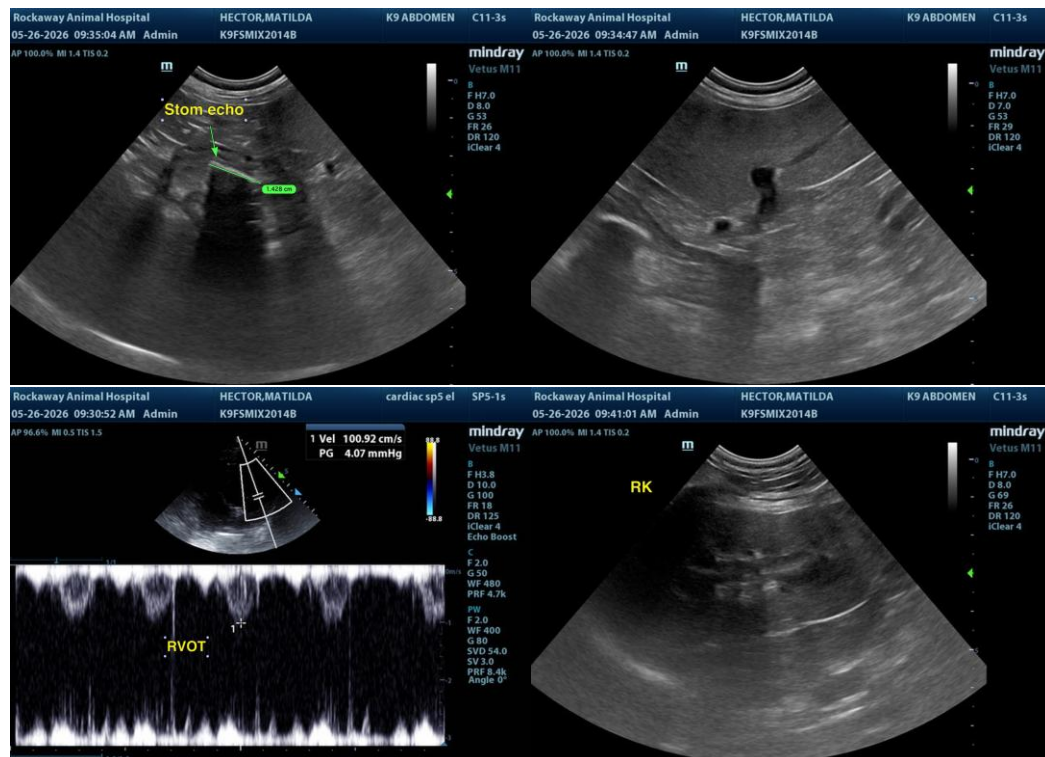
Dr Dubos

INVOICE

24939

DATE

05/26/2026





PATIENT

Matilda Hector

SPECIES

Canine

BREED

Mixed

SEX

FS

AGE

11

WEIGHT

42.6

INTERPRETED BY

R. McKenzie Daniel,
DVM, DABVP
(Canine and Feline)

IMAGING PERFORMED BY

Jenn

HOSPITAL NAME

Rockaway Animal
Hospital

REFERRING VET

Dr Dubos

INVOICE
24939

DATE

05/26/2026



The information and recommendations provided are based on the images presented by the referring veterinarian/sonographer. No evaluation can be communicated regarding pathology that was not



PATIENT

Matilda Hector

visible in the image/video clips provided.

Thank you for this referral. If the clinical or image interpretation does not parallel your findings or if I can be of any further assistance, please contact me.

SPECIES

Canine

R. McKenzie Daniel, DVM, DABVP (Canine/Feline Practice)
info@sonopath.com

BREED

Mixed

SEX

FS

AGE

11

WEIGHT

42.6

INTERPRETED BY

R. McKenzie Daniel,
DVM, DABVP
(Canine and Feline)

IMAGING PERFORMED BY

Jenn

HOSPITAL NAME

Rockaway Animal
Hospital

REFERRING VET

Dr Dubos

INVOICE 24939

DATE
05/26/2026